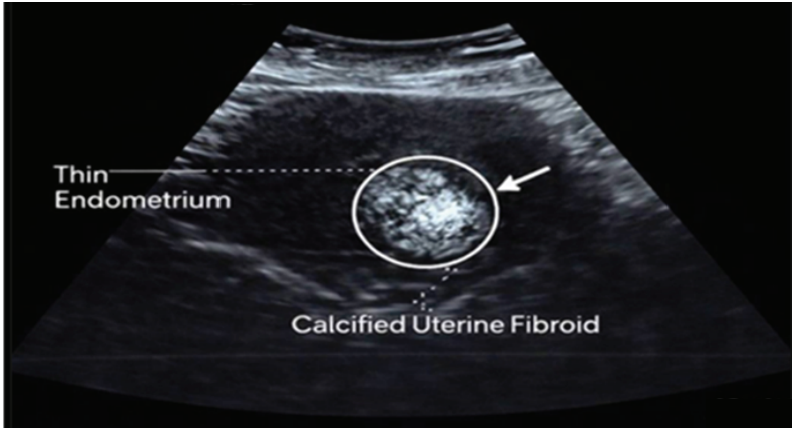


### Supplementary 1.

Transabdominal ultrasound image showing a calcified uterine fibroid with increased echogenicity and posterior acoustic shadowing in a reproductive-age woman.



### Supplementary 2.

Transabdominal ultrasound image showing a non-calcified hypoechoic uterine fibroid in a postmenopausal woman.

